

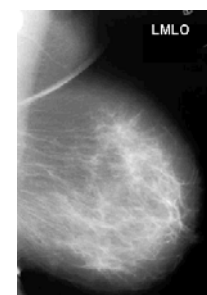


Mammography Word Find



ANSWER THE FOLLOWING QUESTIONS
THEN FIND THE ANSWERS IN THE MAMMOGRAPHY WORD FIND

1. The lateral and **INFERIOR** aspects of the breast are most mobile and if correctly utilised will allow consistent optimal breast tissue visualisation
2. The axillary tail of breast tissue extending towards the axilla is also known as the tail of **SPENCE**.
3. **COOPERS** ligaments provide structural support for the breast tissue.
4. DCIS is commonly indicated on mammography by the presence of **MICROCALCIFICATIONS**.
5. In working up and investigating in determinant calcifications seen on the mammogram, what magnified view is most useful and should ALWAYS be performed **LATERAL**.
6. What are the basic two views taken in mammography?
CRANIO-CAUDAL and Medio -Lateral Oblique.
7. The breast tissue drains *predominantly* to the **AXILLARY** lymph nodes.
8. **MOLYBDENUM** is the common anode target material in mammography.
9. The active glandular breast tissue is known as the breast **PARENCHYMA**.
10. For over 60 years the surgical gold standard for breast cancer was the radical mastectomy named after the surgeon who developed the technique. **HALSTEAD**



11. What would be the most likely diagnosis for a discrete mobile lump in a 25 year old female? **FIBROADENOMA**
12. Which muscle should ideally be demonstrated with adequate width and length to the level of the nipple on the mediolateral oblique views? **PECTORAL**
13. Suspicious areas often need **SPOT COMPRESSION** views to separate superimposed structures by spreading out the breast tissues in a localised area.
14. What filter material is commonly used with molybdenum target for imaging thicker denser breasts? **RHODIUM**
15. The **UPPER OUTER** quadrant has the highest % incidence of breast cancer.
16. What breast core biopsy sampling device is vacuum assisted? **MAMMOTOME**
17. A woman presents with hypoplasia of the Left breast. There is also marked abnormality of the thorax and upper limb on the same side. This looks like **POLANDS** syndrome.
18. The suppressor gene p53 prevents cells with damaged DNA from dividing. Women who are missing this gene have a rare condition called **LI FRAUMENI** making them highly susceptible to a wide range of cancers.
19. Breast MRI of women with breast implants can accurately demonstrate intra and extra capsular rupture. Leakage of the silicon gel can cause the implant shell to collapse and fold in on itself producing the **LIGUINE** sign.
20. A mammographic abnormality which has a spiculated appearance and is evident on only one view could possibly be a **RADIAL SCAR**.

*Thank you very much to the team at **BreastScreen Victoria Radiography Training Centre**, for their tricky questions.*